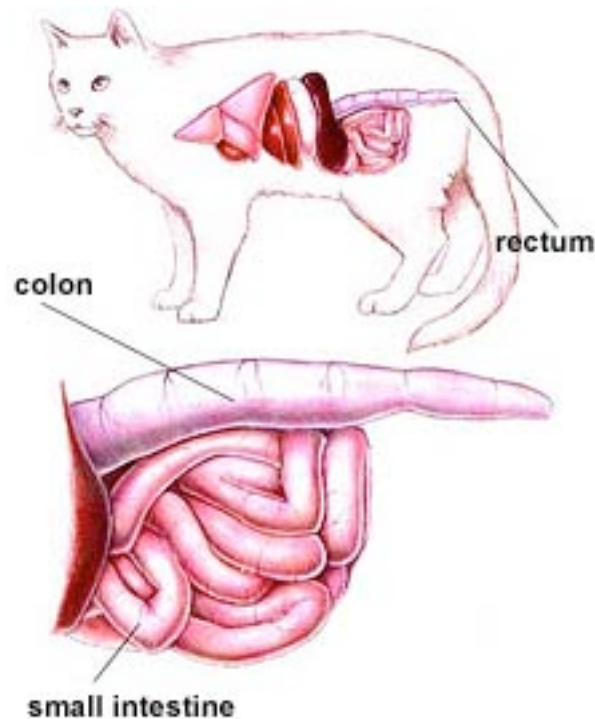




CAYMAN ANIMAL HOSPITAL

Anorectal Foreign Bodies(Fecoliths)

Ingested foreign bodies or hard lumps of feces often lodge in the anal canal or rectum. They are extremely difficult (even impossible) to pass and cause severe pain during defecation.

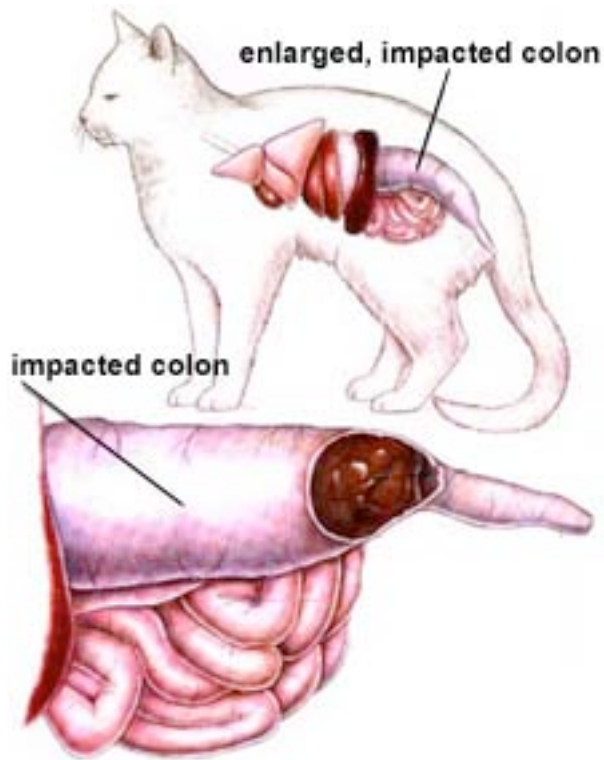


Normal Feline Colon

Bone fragments are the most common anorectal foreign bodies found in dogs. They often pass normally through the upper part of the digestive tract, only to become lodged in the rectum or anus. Fecoliths frequently occur in older cats. A neurologic condition often exists which prevents the animal from defecating normally. Secondary fecal impaction, with accumulation of large amounts of hard feces in the colon, is a common complication resulting from the presence of fecoliths.



CAYMAN ANIMAL HOSPITAL



Impacted Colon in a Cat

Anorectal foreign bodies and fecoliths can often be removed by rectal palpation. Sometimes it is necessary to sedate or anesthetize the animal in order to perform the procedure. In severe cases, surgery is indicated.